

Effect of Crude Aloe Vera Extract on the Histopathology of Gurame Fish (*Osphronemus Gouramy*) Infected with the Bacteria *Edwardsiella tarda*

Nuranti Anarkhis^{1*}, Arief Prajitno², Maftuch³

¹ Master's Degree Program in Faculty of Fisheries and Marine Science, Brawijaya University, Indonesia

² Departement Aquaculture in Faculty of Fisheries and Marine Science, Brawijaya University, Indonesia

³ Departement Aquaculture in Faculty of Fisheries and Marine Science, Brawijaya University, Indonesia

Corresponding author email: nuranti_ar@student.ub.ac.id

Abstract. *Edwardsiella tarda* is a type of gram-negative intracellular pathogen that can cause mass mortality in fish farming. The development of edwardsiellosis due to *E. tarda* infection causes significant economic losses for fish farmers. Aloe vera as one of the plants known to contain active ingredients that can inhibit the growth of bacteria. Aloe vera has a broad spectrum of antibacterial activity, both for inhibiting gram-positive and negative bacteria (Heng et al., 2018). The results of the toxicity test of aloe vera extract showed that when used in high doses it would cause high toxic effects, namely at a dose of 200 mg/L with mortality reaching 60% of the total tested fish. The pathogenicity of *E.tarda* with LD50 showed that the higher the density of bacteria, the higher the possibility that *E.tarda* bacteria could cause disease in its host, namely at a density of 10⁷ it experienced 50% death. The ability of *E.tarda* bacteria to cause disease was also influenced by its host's ability to fight pathogens. Based on the hispatological tests performed, there were changes in the morphology and behavior of the fish. Administration of aloe vera crude extract had an effect, namely being able to reduce the value of histopathological damage to the gills of gourami that had been infected with *E.tarda* bacteria with the lowest score, namely at a dose of 150 mg/L.

Keyword: antibacterial, aloe vera, edwardiella tarda, LC50, LD50, gill histopathology

Introduction

Gouramy is one of the prima donna species of freshwater fish that has high economic value. However, over time, the production of carp cultivation has decreased. One of the reasons for the decline in gourami production is caused by bacterial infection. *Edwardsiella tarda* is a common fish pathogen, causing septicemic diseases and formidable economic losses in freshwater fish farming (Algammal et al., 2022).

E.tarda is a bacterium that causes edwardsiellosis. Edwardsiellosis disease can result in mass mortality and is reported as a serious disease attack for freshwater fish species (Abraham et.al., 2015). Fish infected with edwardsiellosis will show clinical symptoms such as pale skin color, produce excess mucus, have wounds, when scratched they will emit a foul odor, and inflammation occurs from the anus to the base of the tail (Ali et.al., 2014).

Diniarti et.al., (2019) explained that freshwater fish infected with *E.tarda* bacteria experience internal symptoms of damage to vital organs which are usually small white lumps on the gills, kidneys, spleen and sometimes also in the intestines. One organ that is susceptible to bacterial infection is the gill organ. *E. tarda* apart from showing external symptoms in the form of small wounds measuring 3-5 mm, skin necrosis occurs (Maryani, et.al., 2021). In addition, symptoms can also be found that can be seen in the histopathological depiction of the gill organs. For example, there is hyperplasia, edema 2 and even gill cell necrosis in both the primary and secondary lamellae (Lestari et. al., 2018).

The emergence of edwardsiellosis disease is a threat to cultivators and can result in great losses, but the knowledge of cultivators in terms of diagnosing and controlling the disease is still very limited. Therefore it is necessary to make efforts to prevent, treat and control the invasion of *E.tarda*. Generally, drug administration is carried out to treat edwardsiellosis by using antibiotics and chemicals. However, continuous use of antibiotics can cause resistance to microorganisms. Thus, the use of antibiotics for treatment is currently not recommended.

Efforts to reduce the use of antibiotics on a regular basis, it is necessary to use natural ingredients at this time. Natural ingredients are known to have active compounds that can be used as antibacterials. One plant that has an active ingredient is the Aloe vera plant. Aloe vera contains active compounds such as flavonoids, saponins, tannins and flavonoids which have a role in inhibiting bacterial growth. Aloe vera also has various therapeutic properties such as antiviral, anti-oxidant, anti-allergic, anti-inflammatory, anti-cancer, anti-bacterial and has immunostimulating properties (Bendjedid et.al., 2021).

Based on studies on the potential of Aloe vera extract as an antibacterial, many references have been carried out, but its use as an antibacterial alternative to *E. tarda* and its application in fish treatment has not been optimal and has not even been carried out. Thus, the purpose of this study was to examine and study the effect of Aloe vera extract as an antibacterial on the histopathology of gourami fish gills infected with *Edwardsiella tarda* bacteria.

Material & Methods

This research was conducted in November 2021-Mei 2022 in the laboratory of fish parasites and diseases (Faculty of Fisheries and Marine Sciences Brawijaya University), fish reproduction laboratory (Faculty of Fisheries and Marine Sciences Brawijaya University), Laboratory of Organic Chemistry, Faculty of Science and Technology (Sintek), Malang State Islamic University. Materia Medica Batu, Batu City, East Java.

Pathogenicity of E. tarda with LD50

Lethal Dossage 50 (LD50) was carried out to determine how dense and how long *E. tarda* bacteria could kill as much as 50% of the fish tested. The method used refers to the research of Lukistyowati and Kurnianingsih (2011), first the bacteria were cultured on TSB (Tryptic Soy Broth) media of 1010 CFU/ml. Then, multilevel dilutions were carried out with densities of 109 CFU/ml, 108 CFU/ml, 107 CFU/ml, and 106 CFU/ml. Bacterial suspension is calculated using the following formula:

$$N1 \times V1 = N2 \times V2$$

Description:

N1 : Bacterial population density in TSB media (cells/ml)

N2 : Desired bacterial population density (cells/ml)

V1 : The required volume of bacterial suspension in TSB

V2 : Volume of water media in the rearing container

A total of 50 carp were put into 5 tanks, each containing 10 fish. Each tub was filled with 10 liters of water with a bacterial density of 105 cells/ml, 106 cells/ml, 107 cells/ml, 108 cells/ml and 109 cells/ml and then observed for 96 hours. Then, the observations were analyzed using EPA Prohibit Analysis.

Toxicity Test of Aloe vera Extract with LC50

LC50 (Lethal Concentration) is the concentration that will cause 50% of the test organisms to die in testing (Fajri et al., 2016). Determination of LC50 value using extract dose development based on MIC results, namely 50 ppm, 75 ppm, 100 ppm, 125 ppm and 150 ppm. A total of 50 carp were divided into 5 containers containing 10 L of water with a crude extract concentration and then observed for 96 hours. After the extract soaking treatment, the behavior of the test fish was observed and the time and number of fish that died up to 50% were recorded. Observational data were analyzed using EPA Prohibit Analysis.

E.tarda Infection and Soaking of Aloe Vera Extract

In this utilization test, a container in the form of an aquarium was prepared according to the number of treatments. Each container is filled with fresh water. The carp were adapted for 7 days and before infection the fish were fasted for 1 day, then they were infected. The bacteria that were ready on the TSB media were infected into the gouramy live media according to the desired density until they showed signs of being infected. During the treatment process, gouramy fish that had been infected with *E. tarda* bacteria were soaked in a container filled with Aloe vera extract according to the treatment dose. During the rearing period the fish were observed for post-infection and post-treatment histopathology. Then observations were made in the form of fish behavior, appetite and visible damage from outside the fish's body. Feeding is carried out every morning and evening, for cleaning the container is done every 2 days

Data Analysis

The data obtained was analyzed statistically with data using a completely randomized design (CRD). Data was processed and analyzed using the Statistical Package for the Social Sciences (SPSS) 25.0 for Windows software application.

Result dan Discussion

Bacterial Pathogenicity of E. tarda

Bacterial pathogenicity is the ability of bacteria to cause disease. The results of the Etarda bacterial pathogenicity test can be seen in table 1.

Table 1. ETarda Bacterial Pathogenicity Test Results (LD50).

Bacterial Density	Total Test Fish (Tail)	Total Dead Fish (Tail)
10 ⁴	10	1
10 ⁵	10	3
10 ⁶	10	4
10 ⁷	10	5
10 ⁸	10	7

Based on the results of the E.tarda bacterial pathogenicity test using LD50 which was applied to gouramy fish (O.gouramy) for a 96 hour observation time, 50% mortality was obtained at a bacterial density concentration of 10⁷. Several factors are indicators of the occurrence of death in the LD50 test. The pathogenicity of bacteria towards the host varies, one of which is the ability to produce toxins, enzymes, plasmids, overcoming host resistance, as well as the speed of reproduction, and the ability of the host to fight pathogens and bacterial pathogenicity factors (Ipa et.al., 2019).

Aloe Vera Extract Toxicity Test

The toxicity test can be in the form of the death of the test animal and the inability of the test animal to move freely, usually depending on the animal being tested. The results of the toxicity test of aloe vera extract applied to gouramy (O.gouramy) can be seen in table 2, table 3 and figure 1.

Table 2. Toxicity Test of Aloe Vera Extract

Extract Concentration (mg/L)	Total Test Fish (Tail)	Total Dead Fish (Tail)
50	10	0
100	10	0
150	10	0
200	10	6
250	10	7

Description: 96 hours observation time

Based on the results of the toxicity test in Table 2. Treatment with a concentration of 200 mg/L resulted in 60% death while at a concentration of 250 mg/L there was a death of 70%. The results of the toxicity test of crude extract of aloe vera were also known by conducting a probit analysis which was a concentration of 272.44 mg/L with a probit mortality of 100% within 96 hours. Meanwhile, the 50% mortality probit was obtained at an extract concentration of 196.02 mg/L within 96 hours. It can be said that the crude extract of aloe vera can kill 50% of the tested fish at a dose of 196.02 mg/L, which means that the crude extract of aloe vera is toxic at higher doses. The death of the test fish is also thought to be caused by the toxic potential of the

active compounds at certain concentrations. This is in accordance with the research of Anandi et.al. (2021) that the higher or greater the concentration of the extract, the higher the effect or response, namely the death of the test animals.

Aloe vera extract contains active compounds that can be used as antibacterials. The active compounds possessed by aloe vera extract besides being able to change the structure of bacteria, can also be toxic when used in high doses. In the opinion of Rahmani, et al (2020) which states that the toxic effect of aloe vera extract is low when used at the right dose or in other words not using high doses.

Table 3. Toxicity Test Results for Aloe Vera Extract (Probit Analysis).

Extract Concentration (mg/L)	Probit Mortality (%)	Concentration Log
163,52	10	2,21
174,02	20	2,24
182,01	30	2,26
189,12	40	2,28
196,02	50	2,29
203,18	60	2,31
211,12	70	2,32
220,82	80	2,34
235	90	2,37
272,44	100	2,44

Based on the results of the toxicity test in Table 3, treatment with a concentration of 200 mg/L resulted in a death of 60% while at a concentration of 250 mg/L there was a death of 70%. Toxicity test results for crude extract of aloe vera Probit analysis was a concentration of 272.44 mg/L with a probit mortality of 100% within 96 hours. Meanwhile, the 50% mortality probit was obtained at an extract concentration of 196.02 mg/L within 96 hours. The graph of the dose treatment with mortality probit of aloe vera crude extract can be seen in Figure 1.

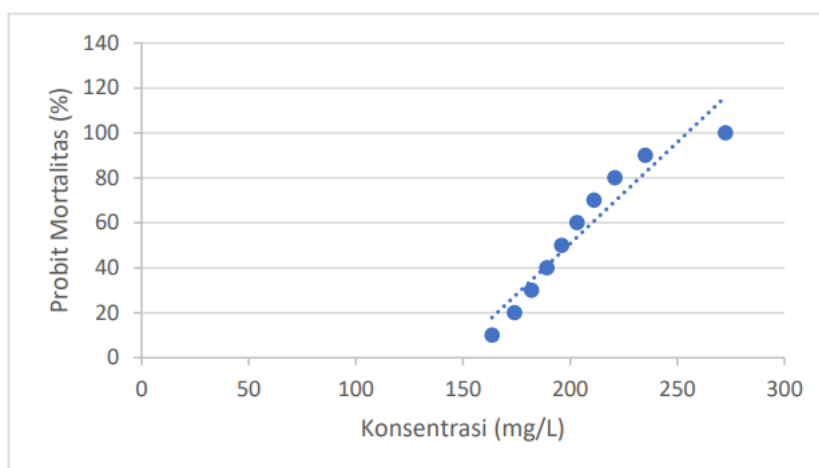


Figure 1. Graph of dosing treatment with probit mortality of crude aloe vera extract

Toxicity test is carried out to see the level of toxicity of a substance and the potential of a substance as an antibacterial. The toxicity test can be in the form of the death of the test animal and the inability of the test animal to move freely, usually depending on the animal being tested.

The toxicity value is the concentration that causes a certain response, both death and immobilization in test animals under controlled conditions (Nugroho, 2018). Toxicity testing shows the behavior of fish when adapting to the environment by actively swimming movements and emerging to the surface of the water to avoid polluted water conditions and seek oxygen intake (Haq et.al., 2020).

Hispathology of Gurami Fish Gills

Histopathology as a method of diagnosing diseases that result in organ damage. Histopathological changes give an overview of damage to the gill organs. Changes in the gill histology of gourami can be seen in Figure 2.

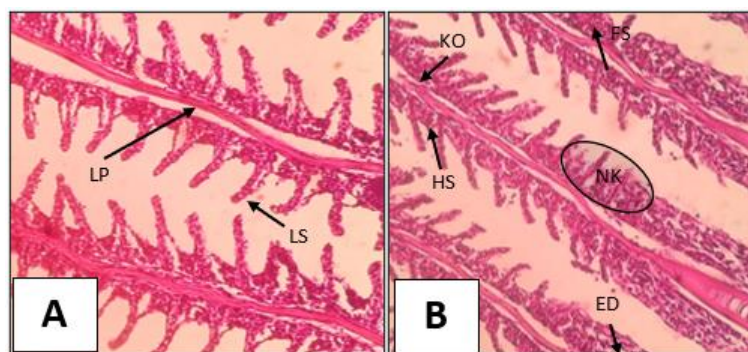


Figure 2. Histology Images of Gourami Gills (*O.gouramy*) (A) Normal fish (K-) and (B) Sick Fish (K+) with Microscope Magnification 400x

Information:

FS = fusion

KO = congestion

ED = oedema

HS = hyperplasia

NK = necrosis

LS = Secondary Lamela

LP = Primary lamellae

1) Hyperplasia

Based on the results of the study presented in Figure 3. there is tissue damage, namely edema in the gills of carp (*O.gouramy*). Gill damage starts from the lightest, namely hyperplasia.

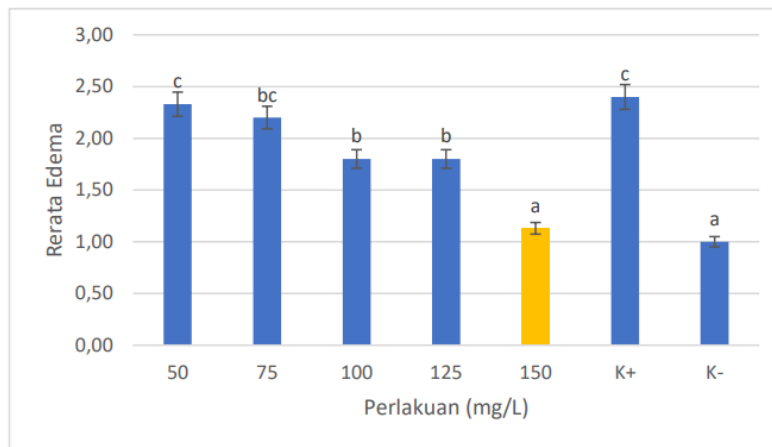


Figure 3. Carp Gill Hyperplasia Suspension Results (*O.gouramy*)

The results of the study then showed that there was an effect of crude extract of aloe vera (*A.vera*) which was able to reduce the value of gill histopathological damage in gouramy infected with *E.tarda* bacteria with the lowest value, namely at an extract concentration of 150 mg/L for hyperplasia damage of 1, 13. Hyperplasia of the lamella tissue, namely the secondary lamella, is characterized by swelling. Hyperplasia that occurs in the lamellae is a response of cells to protect themselves and survive due to bacterial infections, exposure to chemicals and ammonia poisoning (Juanda and Edo, 2018).

Treatment with an extract concentration of 150 mg/L or treatment E was the treatment with the lowest damage with a value of 1.13. Treatment E is the treatment that is closest to the value of scoring damage to healthy fish (negative control). So that the 150 mg/L dose treatment was able to help the test fish in an effort to repair the tissue back to normal conditions when compared to other treatments. This is presumably due to the role of bioactive compounds contained in the crude extract of aloe vera (*A.vera*) such as flavonoids which can stimulate the gouramy body's defense system.

Fusion

The treatment was by administering crude extract of aloe vera (*A.vera*) during the study. It was shown that carp (*O.gouramy*) as the test fish were then infected with *E.tarda* bacteria, giving different average results for each damage that occurred to the gills in the form of fusion. The average pattern of fusion scoring in gouramy is presented in Figure 4 below.

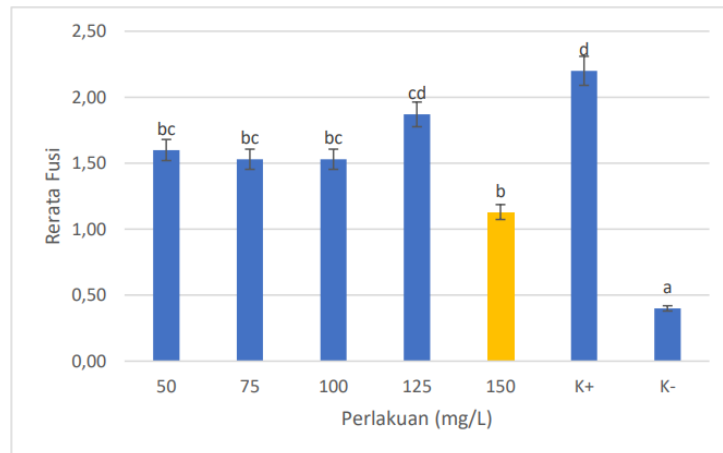


Figure 4. Carp Gill Fusion Suspension (O.gouramy)

The results showed that the administration of aloe vera crude extract (A.vera) had an effect, namely being able to reduce the value of histopathological damage to the gills of gouramy that had been infected with *E.tarda* bacteria with the lowest score being at a concentration treatment of 150 mg/L which was closest to the control of healthy fish (K-) ie 1.13 fusion damage. Treatment E with a concentration of 150 mg/L was the best treatment in this study compared to other treatments.

Fusion in the gills of gouramy infected with *E.tarda* bacterial infection begins with hyperplastic damage and then continues so that fusion occurs and in the end will form vacuoles (empty space) which indicates necrosis. Gills that have changed due to infection with microorganisms will appear enlarged from their normal shape. As a result of the enlargement of the lamellae, the fish have difficulty breathing (Mora et.al., 2022).

Necrosis

The average scoring pattern of edema damage in the gills of carp is presented in Figure 5 below.

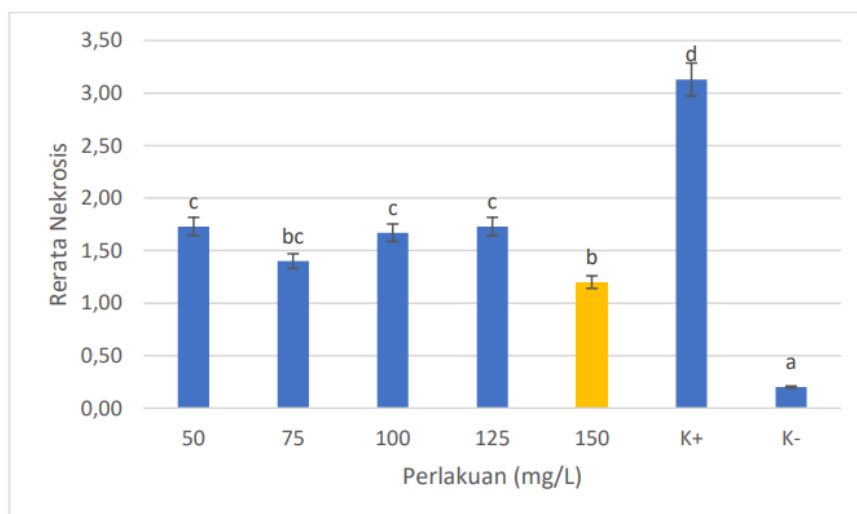


Figure 5. Carp Gill Necrosis Suspension (O.gouramy)

Administration of treatment using crude extract of aloe vera (A.vera) showed a significant effect, namely being able to reduce the value of histopathological damage to the gills of gouramy infected with E.tarda bacteria. Treatment with a concentration of 150 mg/L showed that this concentration had the lowest necrosis damage value compared to the other concentrations, namely 1.20. The concentration of 150 mg/L (treatment E) is the best concentration that is closest to the control of healthy fish (negative control).

Conclusion

The use of Aloe vera extract can reduce bacterial activity but also has toxic properties so it needs to be used in moderation. The treatment of Aloe vera extract in treating gouramy infected with bacteria obtained the best dose of 150 mg/L which can repair damage to the gills of gouramy.

References

- [1] Abraham, T., Mallick, P., Adikesavalu, H. & Banerjee, S. (2015). Pathology of Edwardsiella tarda infection in African catfish, *Clarias gariepinus* (Burchell 1822), fingerlings. *Fisheries & Aquatic Life*, 23(3) 141-148. <https://doi.org/10.1515/aopf-2015-0016>
- [2] Algammal, A. M., Mabrok, M., Ezzat, M., Alfifi, K. J., Esawy, A. M., Elmasry, N., & El-Tarabili, R. M. (2022). Prevalence, antimicrobial resistance (AMR) pattern, virulence determinant and AMR genes of emerging multi-drug resistant Edwardsiella tarda in Nile tilapia and African catfish. *Aquaculture*, 548, 737643.
- [3] Ali, H., F. S. Chowdhury, Ashrafuzzaman, A. N. Chowdhury, R. U. Haque, K. M. A. Zinnah, & M. Rahman. (2014). Identification Pathogenecity, Antibiotic and Herbal Sensitivity of Edwardsiella tarda Causing Fish Disease in Bangladesh. *Current Research in Microbiology and Biotechnology*, 2(1): 292-297.
- [4] Anandi, F., Ferdian, P. R., Pratiwi, J., Amalia, R. L. R., Haerul, H., Fitriana, N., & Nurinsiyah, A. S. (2021). Penapisan Senyawa Aktif dan Uji Toksisitas I_{c50} Lendir Dua Spesies Keong Darat: *Hemiplecta humphreysiana* lea, 1840 dan *Amphidromus palaceus* mousson, 1849 sebagai Sediaan Nutrikosmesetikal Potensial. *zoo Indonesia*, 30(2). Hal. 111-114.
- [5] Bendjedid, S., S. Lekmine., A. Tadjine., R. Djelloul & C. Bensouici. (2021). Analysis of Phytochemical constituents, antibacterial, antioxidant, photoprotective activities and cytotoxic effect of leaves extract and fraction of Aloe vera. p. 1878-8181.
- [6] Diniarti, E., Triyanto dan Murwantoko. (2019). Isolasi, identifikasi dan uji patogenisitas Edwardsiella tarda penyebab penyakit pada ikan air tawar di Yogyakarta. *Jurnal Perikanan*. 21(1): Hal. 41-45.
- [7] Haq, I. A., & Prasetio, E. (2020). Uji Toksisitas Detergen Terhadap Kelangsungan Hidup Benih Ikan Gurame (*Osphrnomus goramy*). *Jurnal Borneo Akuatika*, 2(2). Hal. 102-112.
- [8] Heng, H. C., Zulfakar, M. H., & Ng, P. Y. (2018). Pharmaceutical applications of Aloe vera. *Indonesian Journal of Pharmacy*, 29(3), 101–116. <https://doi.org/10.14499/indonesianjpharm29iss3pp101>.
- [9] Ipa, A., Lukistyowati, I., & Syawal, H. (2019). Profile of Leukocytes Differentiation of Silver Pompano (*Trachinotus blochii*) That Were Fed Using Chicken Feather Meal in Fish Diet Fermented by *Bacillus* sp. *Jurnal Perikanan dan Kelautan*, 24(2) Hal. 106-113.

- [10] Juanda, S. J., & Edo, S. I. (2018). Histopatologi insang, hati dan usus ikan lele (*Clarias gariepinus*) di kota kupang, nusa tenggara timur (Gill, Liver and Gut's Histopathology of Catfish (*Clarias gariepinus*) in Kota Kupang, East West Nusa). *Saintek Perikanan: Indonesian Journal of Fisheries Science and Technology*, 14(1) Hal. 23-29.
- [11] Lestari, W. P., Wiratmini, N. I., & Dalem, A. A. G. R. (2018). Struktur Histologi Insang Ikan Mujair (*Oreochromis mossambicus* L.) Sebagai Indikator Kualitas Air Lagoon Nusa Dua, Bali. *Simbiosis*, 6(2). Hal.45-49.
- [12] Lukistyowati, I., Feliatra, F., & Adelina, A. (2019). Application of probiotic that are in isolation from Giant Prawns and Black Tiger Shrimps on the leukocytes of Nile Tilapia (*Oreochromis niloticus*) infected by *Streptococcus iniae*. 13(2). 309–324.
- [13] Maryani & Rosdiana. (2020). Peranan imunostimulan akar kuning *Arcangelisia flava* Merr pada gambaran aktivasi sistem imun ikan mas (*Cyprinus carpio* L). *Jurnal Akuakultur Rawa Indonesia*. 8(1). 22–36.
- [14] Mora, L., Muttaqien, M., Zainuddin, Z., Salim, M. N., Winaruddin, W., & Jalaluddin, M. (2022). Gambaran Histopatologi Insang Ikan Nila (*Oreochromis niloticus*) yang Terpapar Parasit *Dactylogyrus* sp. *Jurnal Ilmiah Mahasiswa Veteriner*, 6(3).
- [15] Nugroho, R. A. dan F. M. Nur. (2018). *Potensi Bahan Hayati Sebagai Imunostimulan Hewan Akuatik*. Yogyakarta: Deepublish. 109
- [16] Rahmani, R., G. Mohsen., G. Mehran., D. Majid., Jamshidkhan, C., Kayvan, S. and Alireza, H. (2020). Plant-mediated synthesis of superparamagnetic iron oxide nanoparticles (SPIONs) using aloe vera and flaxseed extracts and evaluation of their cellular toxicities. 46 (3): 3051-3058.